



Case Report

ISSN: 2581-3218
IJDR 2019; 4(3): 97-98
© 2019, All rights reserved
www.dentistryscience.com

Endodontic management of a perforated and geminated maxillary first premolar with aid of cone beam computed tomography: A case report

Abbas Basiri¹, Shervin Bagherieh²

¹ Department of Endodontics, Dental Research Center, Hormozgan University of Medical Sciences, Isfahan, Iran

² Department of Endodontics, Dental Research Center, Isfahan University of Medical Sciences, Isfahan, Iran

Abstract

Variations in the root canal morphology have been extensively reported in endodontic literature. Gemination is one rare variation frequently seen in anterior teeth which are defined by two clinical crowns joining in one root. This study reports a maxillary first premolar with gemination. Although uncommon, knowing about this anatomical variation can help in successful endodontic treatment.

Keywords: Gemination, Computed tomography, Cone-beam computed tomography (CBCT).

INTRODUCTION

Locating all root canal orifices, cleaning the whole root canal system and filling the root canal adequately in three dimensions is the most important phase in endodontic treatment [1]. Gemination and fusion are similar dental anomalies in shape, with different etiologies [2], which can bring some clinical challenges in performing root canal treatment [3]. Prevalence of gemination has been reported between 0.06% to 1.1% in different studies, and more frequent in anterior teeth [4-6]. This study reports endodontic management of a geminated maxillary first premolar with the aid of Cone-beam computed tomography (CBCT).

CASE REPORT

A 20-year-old female was referred to Dental School of Isfahan University of Medical Sciences by her general dentist for consultation about endodontic treatment of her maxillary right first premolar (tooth #5). She complained of continuous vague pain in her posterior maxilla. Her medical history was unremarkable. Her maxillary left first premolar was already pulpotomized by her general dentist and did not respond to the vitality tests. Tooth #5 was not painful on palpation and percussion. Her oral hygiene was good and she did not have any periodontal pocket around her maxillary left first premolar. The tooth did not have any sinus tract and the patient had no history of dental trauma. Due to unusual intra-oral shape and weird radiographic appearance, (figure 1A-B) she was referred for a CBCT examination, which revealed a discontinuity in middle portion of root wall at distal aspect of the root in axial view. (figure 2) Non-surgical root canal treatment was planned for her. Local anesthesia was administered by supra-periosteal injection of 2% lidocaine plus 1:80000 epinephrine (Persocaine, DarouPakhsh, Tehran, Iran). Temporary dressing was removed and the access cavity outline was corrected to find possible anatomical variations. A rubber dam was placed for isolation of the tooth. Two orifices were evident in the pulp chamber floor. (figure 3A) Working length was determined with apex locator (RootZX, J. Morita Corp., Tokyo, Japan) and confirmed with periapical radiograph. (figure 3B) Both canals underwent mechanical and chemical debridement with M-two rotary files (25/0.06, 20/0.06, 15/0.05, 10/0.04) (VDW GmbH, Germany) using the standard technique. Irrigation was performed using 5.25% sodium hypochlorite.

After root canal instrumentation, 17% EDTA (Asia Chimi Teb, Tehran, Iran) was used to eliminate the smear layer. After rinsing with saline, the canals were dried with sterile paper points and both were obturated with ortho-MTA (BioMTA, Seoul, Republic of Korea). The tooth was then temporarily restored (Figure 3C). The patient was referred to prosthetic specialist for permanent restoration and a follow-up radiography was taken after twelve months (Figure3D-E).

***Corresponding author:**

Shervin Bagherieh

Dental Research Center, School of Dentistry, Isfahan University of Medical Sciences, Isfahan 81746-73461, Iran

Email: Shervinbgh[at]yahoo.com

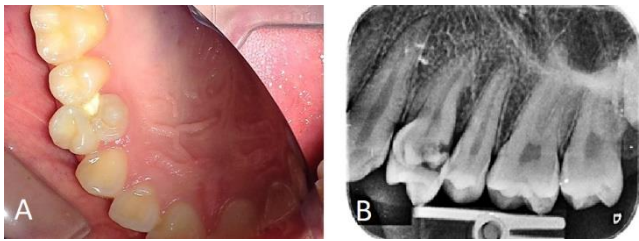


Figure 1: (A) Preoperative intra-oral photography. (B) Preoperative Periapical radiography

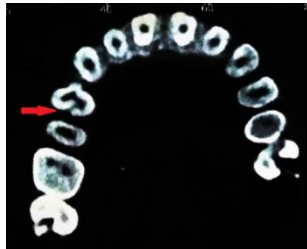


Figure 2: Axial view of CBCT revealing root perforation (red arrow)

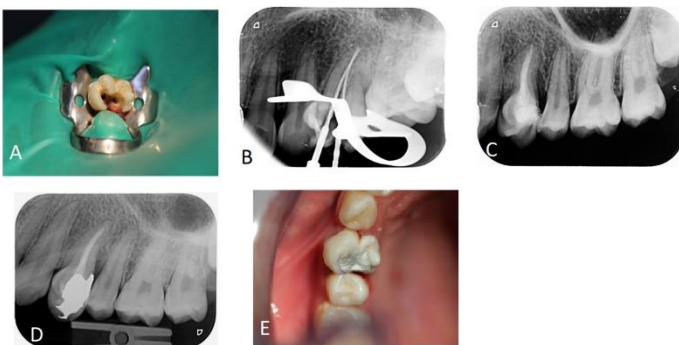


Figure 3: (A) two orifices at pulp chamber floor. (B) Working length radiography. (C) Post operation radiography. (D) 12 month follow up radiography. (E) 12 month follow up intra-oral photography.

DISCUSSION

Gemination and fusion both occur if any alteration happens during tooth development. Because of clinical similarity, it is difficult to distinguish these two dental anomalies. If two separate tooth buds join and form one single tooth, there will be a reduction in the number of teeth present in oral cavity and the process is called fusion. While if a single tooth bud attempts to divide, the number of teeth in the oral cavity will be normal and the process is called gemination [7-8]. Gemination frequently happens in primary dentition and mostly affects the anterior segment of the jaw [9]. Geminated tooth is usually asymptomatic but patient may seek treatment due to aesthetic problems, periodontal breakdown or dental caries leading to pulpal necrosis [10].

More than 98% of maxillary first premolars have one or two roots and regardless of number of roots, they mostly have 2 root canals [11]. Three rooted premolars, radicular premolar or mini molars have an overall prevalence of 1.7% [11-14] and are the most common anatomic variation in this tooth [11]. Current study reported non-surgical management of a maxillary first premolar with gemination and the only study performing root canal treatment on a tooth with this type of variation was reported by Nahmias *et al.* [3]. Their tooth had three clinical crowns and they filled root canals with gutta percha points since there was no perforation detected. However, we used MTA to fill root canals because CBCT revealed a discontinuity in root wall of the tooth. So novel radiographic modalities such as CBCT, which is a high-resolution three-dimensional technique can be a great help in detection of such anatomical variations and possibly change our treatment plan [15].

CONCLUSION

Successful nonsurgical endodontic treatment of geminated teeth has been reported. Owing to the abnormal morphology of the crown and the complexity of the root canal system and perforation found with the aid of CBCT, treatment protocols require special attention. Careful clinical and radiographic examination is essential to successful endodontic treatment. Therefore, clinicians should be aware of anatomical variations to be able to perform an ideal root canal treatment.

REFERENCES

1. Fernández R, Cardona JA, Cadavid D, Álvarez LG, Restrepo FA. Survival of Endodontically Treated Roots/Teeth Based on Periapical Health and Retention: A 10-year Retrospective Cohort Study. *Journal of endodontics*. 2017; 43(12):2001-8.
2. Grover PS, Lorton L. Gemination and twinning in the permanent dentition. *Oral Surgery, Oral Medicine, Oral Pathology*. 1985; 59(3):313-8.
3. Nahmias Y, Rampado M. Root-canal treatment of a trifold crown premolar. *Int Endod J* 2002; 35:390-4.
4. Luke AM, Kassem RK, Dehghani SN, Mathew S, Shetty K, Ali IK, Pawar AM. Prevalence of Dental Developmental Anomalies in Patients Attending a Faculty of Dentistry in Ajman, United Arab Emirates. *Pesquisa Brasileira em Odontopediatria e Clinica Integrada*. 2017; 17(1):1-5.
5. Almaz ME, Sönmez IS, Oba AA. Prevalence and Distribution of Developmental Dental Anomalies in Pediatric Patients/Cocuk Hostolordo Gelisimsel Dental Anomalilerin Gorulme Sikligi ve Dagilimi. *Meandros Medical and Dental Journal*. 2017; 18(2):130-4.
6. Fekonja A. Prevalence of dental developmental anomalies of permanent teeth in children and their influence on esthetics. *Journal of Esthetic and Restorative Dentistry*. 2017; 29(4):276-83.
7. Neville BW, Damm DD, Chi AC, Allen CM. *Oral and maxillofacial pathology: Elsevier Health Sciences*, 2015.
8. S B. Orban's oral histology and embryology: St Louis: Mosby, 1991.
9. White SC, Pharoah MJ. *Oral radiology: principles and interpretation*, 4th ed. St. Louis, MO: CV Mosby, 2000; 311.
10. Grover PS, Lorton L. Gemination and twinning in the permanent dentition. *Oral Surg Oral Med Oral Pathol* 1985; 59:313-8.
11. Ahmad IA, Alenezi MA. Root and root canal morphology of maxillary first premolars: A literature review and clinical considerations. *Journal of endodontics*. 2016; 42(6):861-72.
12. Carns EJ, Skidmore A. Configurations and deviations of root canals of maxillary first premolars. *Oral Surg Oral Med Oral Pathol* 1973; 36:880-6.
13. Kartal N, Özçelik B, Cimilli H. Root canal morphology of maxillary premolars. *J Endod* 1998; 24:417-9.
14. Awawdeh L, Abdullah H, Al-Qudah A. Root form and canal morphology of Jordanian maxillary first premolars. *J Endod* 2008; 34:956-61.
15. Abella F, Morales K, Garrido I, Pascual J, Duran-Sindreu F, Roig M. Endodontic applications of cone beam computed tomography: Case series and literature review. *Giornale Italiano di Endodonzia*. 2015; 29(2):38-50.