



Case Report

ISSN: 2581-3218
IJDR 2020; 5(1): 4-6
© 2020, All rights reserved
www.dentistryscience.com

Direct composite restoration using stamp technique and pizza technique: A case report

Diana Soesilo¹, Yongki Hadinata¹, Fani Pangabdian¹, Linda Rochyani¹

¹ Conservative Dentistry Department, Dentistry Faculty, Universitas Hang Tuah, Surabaya, Indonesia

Abstract

Introduction: The purpose of a restoration is to restore the shape, function, and phonetics and aesthetics of damaged teeth. The disadvantage of direct composite restorations is the formation of dental anatomical structures that require operator skills so that they can optimally restore tooth occlusion. **Case report:** Case 1: A 21-year-old female patient with D4 caries, Site 1 size 2 on tooth number 37 and the patient's dental diagnosis was Reversible Pulpitis. The patient was treated with a composite restoration using the stamp technique. Case 2: A 50-year-old male the patient with D5 caries, Site 1 Size 2 on tooth number 46 and patient's dental diagnosis was Irreversible Pulpitis. The patient was treated with a composite restoration using the pizza technique. **Conclusion:** Stamp technique is indicated for hidden caries in pits and fissures or proximal parts of the tooth with intact anatomical forms. The pizza technique can be used in caries with incomplete anatomical forms but requires operator skills to form biomimetic dental anatomy.

Keywords: Direct composite restoration, Stamp technique, Pizza technique.

INTRODUCTION

The purpose of a restoration is to restore the shape, function, and phonetics and aesthetics of damaged teeth. Restoration consists of 2 types, that are intracoronal or direct restoration and extracoronal or indirect restoration. Direct restoration is a restoration that directly applied in the patient's oral cavity. Indirect restoration was made outside the oral cavity first and then inserted in the patient's oral cavity [1]. Direct restoration is more preferably for small to moderate cavities, the advantage is minimally preparation and the cost is cheaper, but direct restoration requires the skill of the operator. Direct restoration is also not indicated for broad cavities or has reached the subgingival area [2].

A good restoration is a restoration that can resemble the original anatomical shape of a tooth, which is known as biomimetic restoration. The purpose of biomimetic restoration is to form a perfect and complete attachment between the teeth and restoration so that it can reduce functional pressure, eliminate gaps between restoration and teeth, prevent cracks in the teeth due to excessive pressure, eliminate pain and sensitivity of teeth after treatment [3]. Formation of anatomy in restoration is greatly influenced by operator skills thus extending operator work time.

The new technique which is introduced to overcome the problem of anatomic formation is the stamp technique. This technique was introduced by Dr. Waseem Riaz for composite direct restoration that could obtain dental occlusal topography appropriately [4]. This technique is done by taking a mold from the occlusal structure of the tooth before preparation. The problem is this technique only useful for restoring carious teeth with intact occlusal anatomy or hidden caries [5,6].

Another technique introduced is the pizza technique or sectional technique is a modified technique of oblique technique introduced by Manauta and Salat, where each layer is made cusp by cusp like resembling slices of pizza [7]. This technique allows the cavity wall to bind to the composite resin and minimize the possibility edge leakage occurs. Occlusal anatomy can also be formed precisely and accurately so that it can restore the anatomic and aesthetic function of teeth. This technique does not require an intact occlusal like the stamp technique [7,8].

***Corresponding author:**

Dr. Diana Soesilo

Conservative Dentistry
Department, Dentistry Faculty,
Universitas Hang Tuah,
Surabaya, Indonesia
Email:

diana.soesilo@hangtuah.ac.id

CASE REPORT

CASE 1

Female patients 21 years old, came to RSGM with complaints of lower left molar to appear brownish on pit and fissures. Intraoral examination showed caries D4, Site 1 size 2 on tooth number 37. The patient's dental diagnosis was Reversible Pulpitis.

The tooth was isolated with a rubber dam before the cavity preparation stage (Figure 1a). Tooth was smeared with vaseline as a separator. Flowable composite was placed on the occlusal surface of the tooth and then the microbrush was pressed gently to the flowable composite and then polymerized with visible light for 20 seconds to make a stamp/mold of the tooth's occlusal surface (Figures 1b & 1c).

Tooth was cleaned with prophylactic paste to remove vaseline, then caries was cleaned with a round diamond bur. The exposed dentin was coated with a liner (Figure 1d), then 37% phosphoric acid etching was applied with selective etch technique on the tooth enamel surface (Figure 1e). Bonding was applied with a microbrush and polymerized for 20 seconds and then continued with the administration of a packable composite with an incremental technique in which each layer was polymerized for 20 seconds (Figure 1f).

The last incremental layer was given a clear plastic wrap on its surface then the stamp made on the microbrush which was pressed gently on the plastic (Figure 1g & 1h). The stamp and plastic were lifted slowly then the excess composite was cleaned with a sharp hand instrument, then polished the composite (Figure 1i).

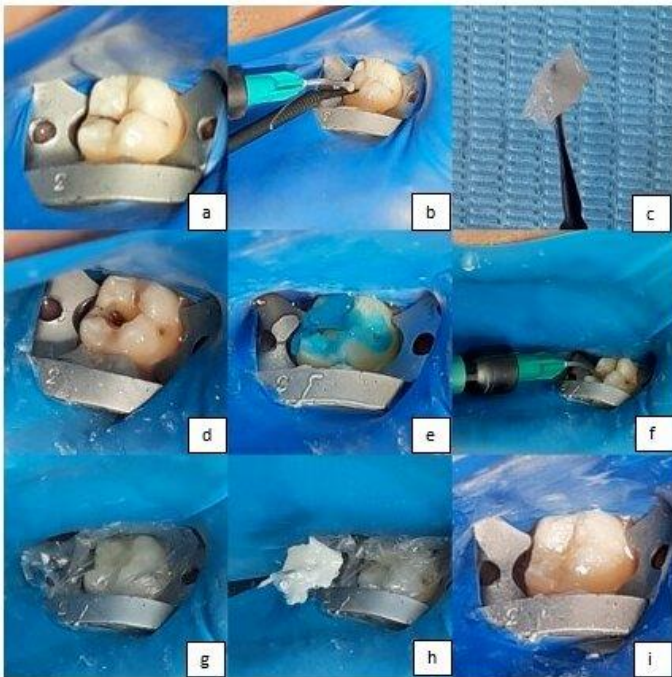


Figure 1: Composite restoration steps with Stamp technique

CASE 2

Male patients 50 years old, came to RSGM with complaints of sharp tooth pain in his lower right molar teeth when drinking ice. Intra oral examination showed caries D5, Site 1 Size 2 on tooth number 46. Dental diagnosis of patients was Irreversible Pulpitis.

The tooth was isolated with a rubber dam before cavity preparation (Figure 2a). Caries was cleaned with a round diamond bur and excavator. Thin enamel was rounded with a fissured diamond bur. The exposed dentin was coated with a liner (Figure 2b), then applied etching 37%

phosphoric acid with a selective etch technique on the tooth enamel surface (Figure 2c). Bonding was applied with a microbrush and polymerized for 20 seconds.

The cavity was restored with a packable composite using incremental layering technique. The pizza technique procedure started from the mesiobuccal cusp with a thin layer of composite resin, then was polymerized with visible light for 20 seconds (Figure 2d). After the first cusp was polymerized, then the distobuccal cusp was formed and polymerized. Next, the distolingual and mesiolingual cusps were formed in a clockwise direction (Figure 2e). Slopes and sulcus were formed by microplugger and final polymerized (Figure 2f). Then the occlusion was checked by articulating paper and polished.

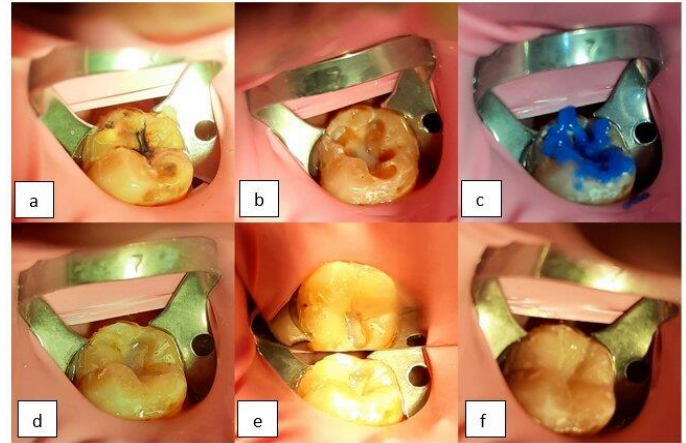


Figure 2: Composite restoration steps with Pizza technique

DISCUSSION

Biomimetic restoration is a restoration made in such a way as to resemble natural teeth and to obtain a harmonious cusp-fossa relation between antagonistic teeth and their neighboring teeth, which lasts for a long time, increases the vitality of the pulp, reduces residual pressure. Biomimetic restoration protocols are divided into 2 groups, which are protocols to reduce masticatory pressure and protocols to maximize bonding between teeth and restoration material [9].

Direct restorative material that is often used for tooth biomimetic restoration nowadays is composite resin. Based on a survey conducted by researchers at the University of Otago New Zealand, the use of composite resins for the posterior tooth restoration in the occluso-proximal portion of premolars were 93.7% and permanent molar teeth at 85.2% [10]. Factors affecting the increased use of composite resins as the restoration material are due to the color of the teeth so that the aesthetics are good, minimal tooth preparation, low edge leakage if the application of the bonding is correct, does not conduct heat, is easily formed in a long working time, can be polished at one visit resistance to fracture and moderate wear, durable with a restoration replacement period of around 8 years [11,12].

The disadvantage of composite resins is that they shrink when polymerized with visible light. Composite shrinkage will cause gaps between the composite resin and teeth which can cause postoperative sensitivity, secondary caries, failure of attachment to the tooth surface, restoration or tooth fracture. Composite shrinkage is also affected by the configuration of factor C, which is the ratio between the restoration surfaces that bind to teeth and those that are not bound to teeth. The higher the ratio of factor C, the higher the rate of composite shrinkage. Three-dimensional cavity preparation as in class I and class V cavities has the highest rate of shrinkage. Composite shrinkage can be reduced by reducing the monomer level, increasing the molecular weight of the monomer, modifying the composite layering technique on teeth, and modifying the polymerization technique [1,12,13].

The composite placement technique used to reduce composite shrinkage is the incremental layering technique in which the thickness of each layer is a maximum of 2 mm so that perfect polymerization of the composite resin can occur so as to reduce the shrinkage pressure during polymerization. Pizza technique is a modification of the incremental layering technique. This technique is done by applying one layer to each tooth cusp. Each of these layers when formed, resembles slices of pizza. The procedure starts with a simple cusp then adds another cusp to obtain a shape that is more in accordance with anatomy. Placement of composites with this technique in addition to having a biomimetic anatomical form also reduces the pressure of composite shrinkage by reducing factor C in class I from a ratio of 5 to 1 [6,7,14].

Another biomimetic restorative technique is the stamp technique. Stamp functions as an index to replicate the occlusal anatomical shape of teeth. This technique is done by taking a negative impression of the occlusal surface anatomy of a tooth on a carious tooth with an anatomic structure that is still good or intact. Cases with wide or irregular cavities can be made mock up first with a new wax then printed with flowable composites to make a stamp [4,15]. The base of cavity restored with incremental layering techniques to reduce composite shrinkage during polymerization. The pressure applied when printing composite resin with a stamp can reduce the formation of micro bubbles and the effect of oxygen during the polymerization period in the last layer thereby reducing the degree of porosity and increasing the resistance of the composite. This technique also requires a fairly short polishing time [6,9].

CONCLUSION

Each restoration technique both stamp technique and pizza technique has advantages and disadvantages. The advantage of stamp technique is that it can obtain the exact anatomical shape of the tooth or biomimetic without requiring operator skills and simplifies the process of polishing the composite so as to further shorten the work time. The disadvantage is that this technique is only indicated for caries with occlusal anatomy that is still intact as in pit and fissure or caries site 2 which is located at the margins and is still covered with enamel in the occlusal. The pizza technique can be performed on caries which is quite extensive, irregular in shape, and can reduce composite shrinkage during polymerization, but requires operator skills and requires a longer working time.

Conflict of Interest

The author reports no conflicts of interest.

REFERENCES

1. Garg N, Garg A. Textbook of Operative Dentistry. 3rd ed. New Delhi. Jaypee Brothers Medical Publishers (P) Ltd; 2015. p. 5,115,
2. Opdam NJM, Frankenberger R, Magne P. From 'Direct Versus Indirect' Toward an Integrated Restorative Concept in the Posterior Dentition. Operative Dentistry supp 7. 2016. p. 27-34
3. Alleman, DS, Nejad MA, Alleman CDS. The Protocols of Biomimetic Restorative Dentistry : 2002 to 2017. Inside Dentistry. June 2017. p. 64-73
4. Mary G, Jayadhevan A. Microbrush Stamp Technique to Achieve Occlusal Topography for Composite Resin Restoration - A Technical Report. Journal of Scientific Dentistry; 6(2). 2016. p. 76-82
5. Aleshadat SA, Halim MS, Carmen K, Fung CS. The Stamp Technique for Direct Class II Composite Restorations : A Case Series. J Conserv Dent. 2016; 19. p. 490-493
6. Shikha S. Biomimetic Dentistry Using Stamp Technique for Direct Posterior Composite Restorations : A Case Report. Acta Scientific Dental Science 3.9 (2019). p. 69-73
7. Manauta J, Salat A. Layers : An Atlas of Composite Resin Stratification Style Italiano. 1st ed. Berlin. Quintessence. 2012. p. 277-279

8. Nugroho JJ, Trilaksana AC, Rovani CA, Natsir N, Rahim F. Pizza Technique in Site 1 Restoration in Lower Second Molar Tooth : A Case Report. Journal of International Dental and Medical Research 2019; 12(2). p. 723-726
9. Tambake NJ, Tambake S, Gandhi N, Jadhav Y, Madhu K, Burad P. Stamp Technique- New Perspective of Aesthetics Dentistry : A Case Report. IOSR Journal of Dental and Medical Science ;16 (6) ver. XII. 2017. p. 49-51.
10. Loch C, Ratnayake J, Veerasmy, A, Cahthro P, Lee R, Brunton PA. Direct Restoration, Endodontics, and Bleaching : Materials and Techniques Used by General Dentist of New Zealand. Hindawi International Journal of Dentistry. 2019. p. 1-7.
11. World Health Organization. Future Use of Materials for Dental Restoration. Geneva. 2010. p.8-12
12. Divakar KP, Regish KM, Bawa S. Polymerization Shrinkage of Composite Resins: A New Perspective To An Old Problem - A Review. International Journal of Healthcare and Pharmaceutical Research vol. 3 no. 3. 2014. p. 25-28
13. Chan KHS, Mai Y, Kim H, Tong KCT, Ng D, Hsiao JCM. Review : Resin Composite Filling. Materials Journal vol 3. 2010. p. 1228-1243
14. Chandrasekar V, Rudrapati L, Badami V, Tummala M. Incremental Techniques in Direct Composite Restoration. Journal of Conservative Dentistry 20(6). 2017. p. 386-391.
15. Pompeu JGF, Morais RC, Ferreira TO, et al. Occlusal Stamp Technique for Direct Resin Composite Restoration : A Clinical Case Report. Int J Recent Sci Res; 7(7). 2016. p.427-430.