



Case Report

ISSN: 2581-3218

IJDR 2021; 6(2):30-32

Received: 09-06-2021

Accepted: 07-07-2021

© 2021, All rights reserved

www.dentistryscience.com

doi: 10.31254/dentistry.2021.6202

Bilateral Transmigration of impacted maxillary canines - Kissing Canines- Case study

Hana Al Kiyumi¹, P.S Viswapurna², Mohammad Zeinalddin³

¹ Department of Orthodontics, Oman Dental College, Muscat, Oman

² Consultant and Head of Orthodontics, Oman Dental College, Muscat, Oman

³ Craniofacial Orthodontist, Mohammad Orthodontic Center - Senior lecturer and Course Coordinator, Oman Dental College, Muscat, Oman

Abstract

An un-erupted permanent canine crossing the midline is called transmigration and is considered to be an unusual event.¹ The incidence of maxillary canine impaction ranges between 0.8–2.8%. The proper diagnosis of the transmigrated canines is achieved by radiographic evaluation. In this case report a rare phenomenon of bilateral impacted and migrated maxillary canines in a kissing position is discussed.

Keywords: Impaction, Transmigration, Maxillary canine, Kissing canines, Orthodontics

INTRODUCTION

Transmigration is a rare anomaly that usually affects the mandibular canines. It is defined as a tooth that crosses the midline by more than half its length. The etiology for its occurrence is unknown and the exact mechanism is still not clear; however, there are many etiological factors which might lead in transmigration of the teeth. The various probable factors are ectopic growth of the tooth bud, retention or premature loss of a primary tooth, inadequate eruption space and excessive length of crown. Genetic factors, endocrine disorders and trauma have also been anticipated as etiological factors^[1].

Literatures report that bilateral transmigration of canines is rare; however transmigration of mandibular canines is much higher than those of maxillary canines^[2].

Qaradaghi gave the name “kissing canines” or “mirror image canines”, which is defined as “the migration of both canines at the same rate and on the same horizontal axis parallel to each other and meeting each other at the midline”^[2].

In general, the transmigrated canine remains impacted, but sometimes it can erupt labially,

lingually or in mirror image manner with the contralateral canine^[3].

There are limited numbers of studies on the incidence of maxillary canine transmigration^[4].

In 2011, a study was published which reported six cases of maxillary canine transmigration in a total of 4500 patients and before this study, only one case of maxillary canine transmigration had been reported^[3,4]. Due to the lack of published reports on maxillary canine transmigration cases, the transmigration patterns of the canines is not well known^[4].

CASE REPORT

A 28-year-old male patient presented with a chief complaint of crooked front teeth. Intraoral examination showed fair oral hygiene, class I molar relationship on right and left buccal segments, class II div 2 incisor relationship with 100% overbite. There was retained upper right primary canine (FDI 53) and remaining root of upper left primary canine (FDI 63). Both maxillary permanent canines were clinically missing. [Figure 1]

***Corresponding author:**

Dr. Mohammad Zeinalddin

Craniofacial Orthodontist,
Mohammad Orthodontic Center
- Senior lecturer and Course
Coordinator, Oman Dental
College, Muscat, Oman

Email:

mzeinalddin@staff.omandentalc
ollege.org

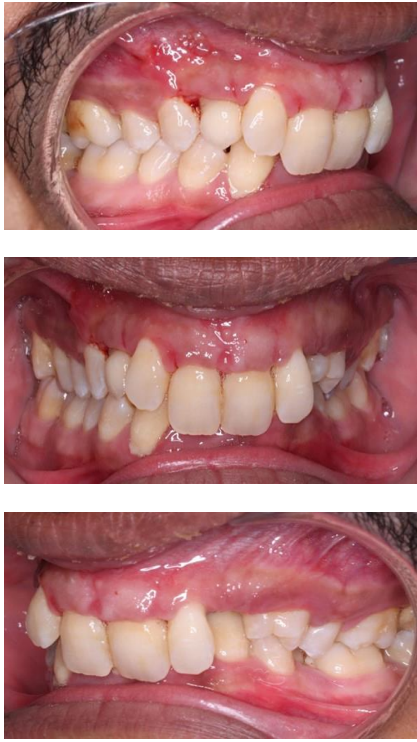

Figure 1: Intraoral photos

The intraoral periapical and Orthopantomogram radiographs revealed bilateral horizontally impacted permanent maxillary canines with the crowns facing each other in a kissing position in midline of the upper dental arch. They were above the roots of upper central incisors [Figure 2 a, b]

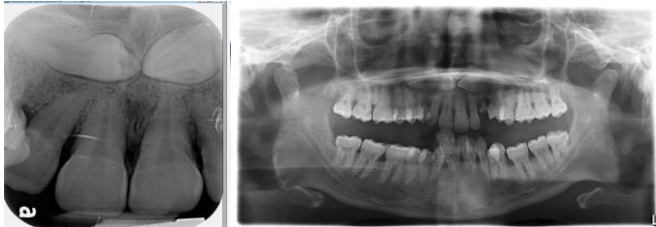
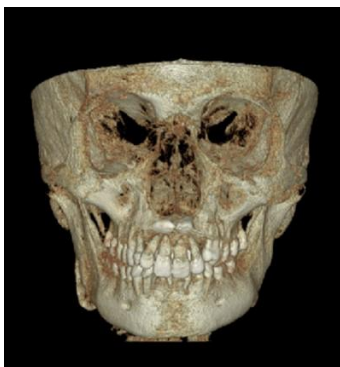
Figure 2: a) Periapical radiograph. b) Orthopantomogram



CBCT was taken as a gold standard radiograph and confirmed the actual position of the impacted maxillary canines. It revealed that both canines were highly buccally placed inferior to the nasal floor and horizontally impacted. Crowns were placed above and in a close proximity to the root tips of upper left and right central incisors. No resorption was seen to the adjacent root apices. Crown tips were contacting and facing each other (Kissing canines). The radiographic examination suggested that both impacted canines were highly unfavorable requiring surgical removal which was planned under local anesthesia.

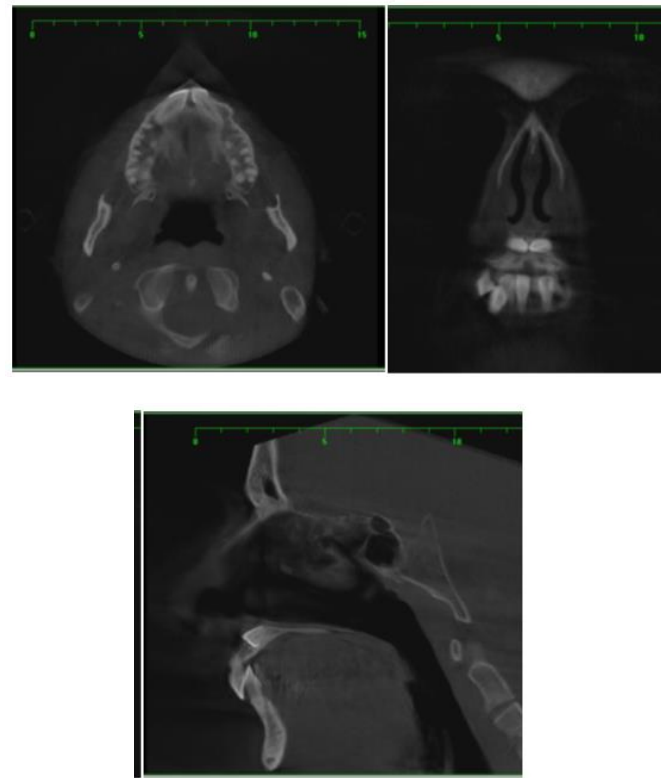


Figure 3: a. Coronal view, b. Sagittal view c. Axial view d. 3D View

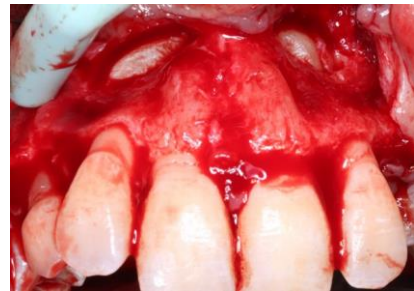

Figure 4: Front view

DISCUSSION

Mandibular canine transmigration is almost exclusively reported as dental transmigration in literatures. The reported incidence for this phenomenon ranges from 0.8–3.6% to 0.1% [1].

The prevalence of canine impaction is more in the maxilla than in the mandible, but transmigration of mandibular canines are more frequent than those of maxillary canines.

To this point, very few cases have been reported regarding the bilateral type of transmigration which is a very rare presentation.

CONCLUSION

Canine transmigration is defined as un-erupted permanent canine crossing the midline. Multiple etiological factors for canine transmigration have been proposed, but the exact mechanism of its occurrence is not well known. Radiographic evaluation is essential to diagnose canine transmigration. The most common choice of the management of transmigration tooth involves surgical extraction.

Conflict of interest

The author reports no conflicts of interest.

REFERENCES

1. Tiwari R, Mathew P, Jose Y, Tiwari H, David J. Kissing Canines: Impacted & Migrated: Case Report. *International Journal of Applied Dent Science*. 2018; 4(4):22-4
2. Garg A, Agarwal S, Agarwal S, Mittal S, Singh P. Pattern of bilateral transmigration of impacted mandibular canines: A radiographic study of 3 cases. *J Evid Based Med Health*. 2015;2:921-8.
3. Fortuna T, Freitas A, Reboucas D. Transmigration of a Maxillary Canine. A Case Report. *Research gate*. 2017;20(2):132-8
4. Aydin U, Yilmaz H, Yildirim D. Incidence of canine impaction and transmigration in a patient population. *Dentomaxillofacial Radiology*. 2004; 33:164-9.
5. Mazinis E, Zafeiriadis A, Karathanasis A, Lambrianidis T. Transmigration of impacted canines: prevalence, management and implications on tooth structure and pulp vitality of adjacent teeth. *Clin Oral Inves*. 2012;16:625-632

HOW TO CITE THIS ARTICLE-

Kiyumi1 HA, Viswapurna PS, Zeinalddin M. Bilateral Transmigration of impacted maxillary canines - Kissing Canines- Case study. *Int J Dent Res* 2021; 6(2):30-32. doi: 10.31254/dentistry.2021.6202

Creative Commons (CC) License-

This article is an open access article distributed under the terms and conditions of the Creative Commons Attribution (CC BY 4.0) license. This license permits unrestricted use, distribution, and reproduction in any medium, provided the original author and source are credited. (<http://creativecommons.org/licenses/by/4.0/>).